

CranioSacral Therapy  
and the  
Treatment of Post Concussion Syndrome

Although Craniosacral Therapy (CST) is not a panacea for all post concussion symptoms, it can be a powerful adjunct to the care of individuals whose lives and those of their families have been severely altered as a result of these symptoms. Success has been reported clinically by advanced practitioners of CST. Documented results in pilot studies have garnered interest by professional medical researchers.

Concussion is the result of the head hitting an object or a moving object hits the head. Concussion can also occur when the head and neck are subjected to violent movements without directly contacting an object. This can occur during a whiplash type of injury. In this instance, it is referred to as a contrecoup injury in which the brain is thrown against the inside of the cranium. This force then moves the brain toward the opposite side of the skull resulting in another forceful contact. Repeated hits resulting in concussion such as athletes participating in football and soccer can lead to a cumulative development of symptomology.

Depending on the amount and direction of the force, vasculature to the brain tears and internal bleeding occurs. Also damaged are the neurons, neuronal centers and glial tissue which support the various brain structures. The resulting damage in function varies across a continuum. Symptoms may not show up until later, sometimes a year or more. This is referred to as post concussion syndrome. Symptoms are wide ranging and can affect an individual in a variety of ways. Emotionally and behaviorally, a person may become more irritable and aggressive. Anxiety, depression, apathy and other changes in personality may also occur. Cognitive dysfunction may exhibit itself with difficulties in concentration

and memory. Physically, there may be headaches, neck pain as well as other seemingly unrelated pain syndromes and system disorders. For example, damage to the pituitary or surrounding tissues may affect endocrine function. Other common physical symptoms include dizziness, tinnitus, double vision, sleep disorders and fatigue.

Although there is some debate as to what causes postconcussion syndrome, including risk factors associated with preexisting psychological conditions, physical changes to the brain is considered by many to be a primary cause. There are professionals who argue that the structural damage and possible disruption in the transmission of neurotransmitters causes the dysfunction associated with post concussion syndrome. Practitioners of CST who work with the various structures of the brain and tissues that affect the brain and cranium have found this to be true.

Anatomically, the craniosacral system (CSS) is the deepest layer of the fascial system, a continuous network surrounding every structure of the body. There is even evidence that strands of fascia pierce the cellular membrane and connect to the nucleus of the cell. Tensile strength of the fascial network has been measured up to 7,000 pounds per square inch. These forces combined with the continuity of the fascia helps to explain the myriad of symptoms that an individual may experience after an injury *should* have healed. Post concussion syndrome is one example among many illustrating the affects of a tight fascial system on the other systems of the body.

The anatomy of the CSS is relatively simple. The cranium is lined with dura mater, which not only encircles the inner surfaces of the cranial bones, but also folds in on itself creating the falx cerebri, tentorium cerebelli and the falx cerebelli otherwise known as the intracranial membrane (ICM). The firm attachment of the falx cerebelli at the foramen magnum of the occiput continues inferiorly with

attachments on the posterior bodies of C1 and C2. It continues in the inferior direction without any attachments until it anchors at the S2 segment as the pia portion of the filum terminale within the sacral canal. It exits out of the sacral canal and continues as the external dural segment of the filum terminale blending with the periosteum of the coccyx. (Figures 1a,b,c) In addition, the dura mater extends out through the intervertebral foramina with the spinal nerves as the dural sleeves. The dural sleeves attach on the vertebral bodies blending with the paravertebral fascial tissue. These anatomical attachments help give credence to the continuity of the fascia and why CST has such far reaching affects.



Figure 1a: Dural Attachments to Bone/Skull

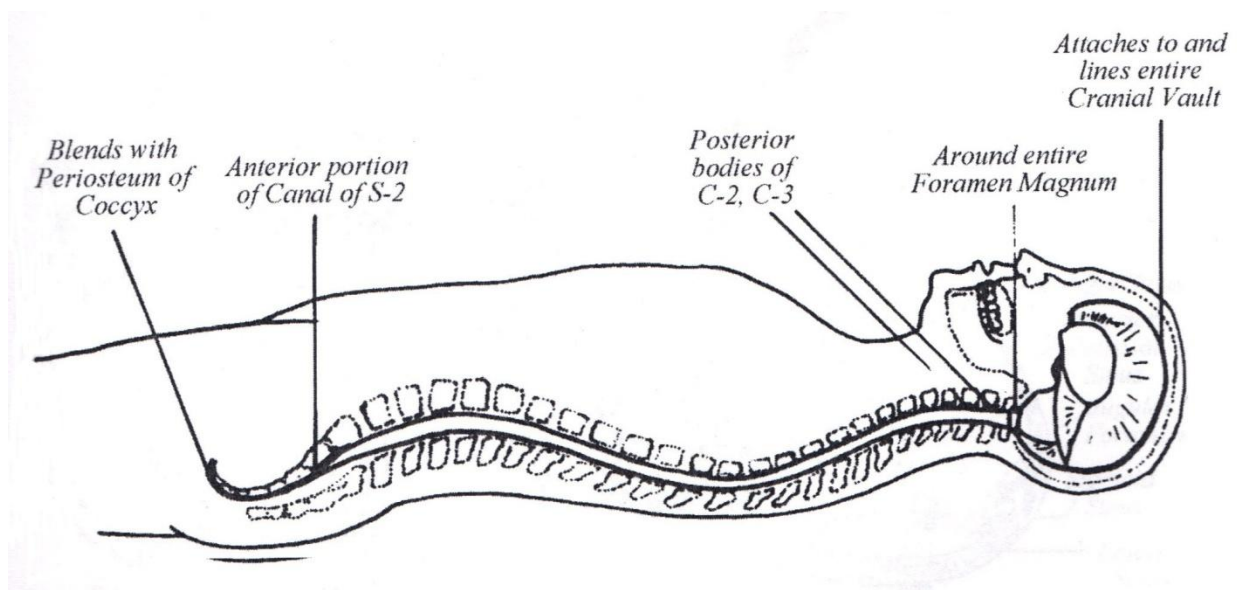


Figure 1b: Detail of dural attachments including intracranial membrane

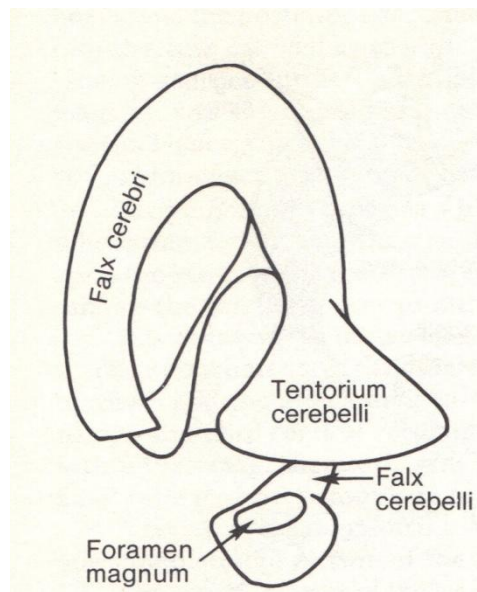


Figure 1c: Intracranial Membrane Detail

There is normally a palpable movement of each of the cranial bones around a specific axis. The scientific validity of cranial bone movement is explored in the article *"Craniosacral Therapy...What is it Really?"* which can be accessed at

Upledger.com. Restricted cranial bone movement reflects not only sutural restrictions but also restriction in the underlying meninges attaching to the bone. CST techniques address both types of limitations in mobility.

Concussion affects the structures of the nervous system including the glial cells which are the glue or supporting matrix of the structures of the brain. This glial matrix, although of different embryonic origin than the fascia, shares some similar functions. The extracellular fluid matrix transports nutritive substances and removes waste products as well as information via micro biochemical substances. Disturbances of this fluid may inhibit communication between various parts of the brain. The glial cells extend all the way out to the cortical layer of the brain via the glial end feet. These end feet connect directly to the pia mater which is a shrink wrap-like layer for the brain. This pia layer connects to the dura mater of the CSS via the arachnoid layer of the meninges. Trauma affects the bones of the cranium and the dura mater lining the inside of the skull bones as well as the sensitive brain tissue. It is suspected that the positive results experienced with CST in post concussion syndrome are the result of affecting not only the dura and cranial bones but also the glial network attaching directly to brain structures they support via this meningeal connection.

CST includes mobilization of each of the bones around its anatomical axis affecting the attaching membrane and the glial network that attaches directly to the meninges of the nervous system. A frontal lift technique can address tension patterns related to the frontal lobe associated with executive function and concentration. This can affect behavioral changes associated with impaired decision making and focus. Temporal techniques may address the tinnitus and dizziness symptoms associated with post concussion syndrome. All of the techniques have the potential to affect the functioning of the deeper structures of the brain via the glial matrix connection to the meninges of the brain that directly attach to the skull bones.

Post Concussion Syndrome and the associated symptoms have clinically responded to CST. CST continues to generate interest and scientific investigation as a viable adjunct in the care of individuals experiencing the adverse affects of post concussion syndrome. Meanwhile, those suffering from the effects of concussion seek out Craniosacral Therapy as a means to improve function and decrease pain.

## Bibliography

1. Ricky Williams Pilot Concussion Program . Palm Beach Gardens: Upledger Institute, July 2014.
2. **Barral JP, Crobier A.** Trauma: An Osteopathic Approach. Seattle, WA: Eastland Press, 1999.
3. **Encyclopedia, A.D.A.M. Medical.** Diseases and Conditions > Concussion. *U.S. National Library of Medicine -Pub Med Health*. [Online] January 15, 2014. [Cited: November 29, 2014.] ncbi.nlm.nih.gov.
4. **Debangus.** Pst-concussion syndrome. *Wikipedia*. [Online] November 8, 2014. [Cited: November 29, 2014.] en.m.wikipedia.org.
5. **Cydebot.** Extracellular Matrix. *Wikipedia*. [Online] November 27, 2014. [Cited: November 29, 2014.] en.m.wikipedia.org.
6. **Wanveer, Tad.** *The Pia-Glial Connection*. Upledger Update: Palm Beach Gardens, FL: Upledger Institute.
7. **Felton D, Jozefowicz R.** *Netter's Atlas of Human Anatomy*. Teterboro, NJ: Icon Learning Systems, 2003.
8. **Upledger JE, Vredevoogd, JD.** *Craniosacral Therapy*. Seattle, WA : Eastland Press, 1983.
9. Gratz, CM. *Tensile Strength and Elasticity Tests on Human Fascia Lata* J Bone Joint Surg, 1931, Vol. 13.
10. **Paoletti, S.** *The Fasciae*. Seattle, WA: Eastland Press, 2006.
11. **Sisco, M.** *Craniosacral Therapy...What is it Really?* . CyberPT.com [Online] June 20, 2012. [Cited: November 29, 2014.]

